

The Treatment of Gangrenous Diabetic Abscess by the “Ring of the Dragon” Acupuncture Technique

by Shmuel Halevi

Introduction

During the past ten years I have had the opportunity to treat more than 20 cases of diabetic foot syndrome in my clinic. The most difficult cases were those which developed the so-called soft-tissue abscess, or ulceration, some of which exhibited the first signs of progressive gangrenous inflammation. These patients usually exhibited large ulcers, very ugly-looking and foul smelling, in various parts of the shin or foot. In most cases, they were immediate candidates for amputation, as moderate conventional Western medical modalities had failed to improve their condition. In view of this standard prognosis, it is perhaps striking that I managed to achieve a 90% success rate in curing this disease by means of traditional acupuncture alone. The remaining 10% failed treatment mostly because of premature cessation of the treatment, principally due to financial hardship. Two of the cases which I treated recently, had developed cancerous cells on the site of the abscess as well. These cases were also completely cured.

I do not pretend to claim that these few patients can present a reliable statistic for the cure of this disorder, yet it is undoubtedly worth the attention of the medical world for further investigation. It also goes without saying that there are enormous implications involved in saving an individual's limb, as against the present widespread procedure of amputation and the patient's subsequent suffering and incapacity.

The following case study is of a 65 year old patient of mine, Joseph, who luckily was cured of a gangrenous abscess on his left dorsal surface, “a minute” before undergoing an amputation procedure. He graciously agreed to let me present a few photographs taken during the course of the treatment, showing the gradual improvement of his foot condition. I believe that this article may be of value to those acupuncturists who have had no prior experience in

the treatment of such disorders. I am however, sceptical that this article will encourage further investigation by any conventional medical institutions.

Preliminary acquaintance

I came to know Joseph two years before he presented with the dorsal abscess. He was already an insulin dependent diabetic, and he came to see me for recurrent attacks of gout in his left big toe and occasionally also in his dorsal fascia. These attacks of gout, he said, started a long time before he knew he was going to have diabetes. When he came to me he was in the midst of a gout attack in his left toe, so harsh that his face was distorted with pain. Painkillers did not help much anymore, and it seemed to him that taking non-steroidal anti-inflammatory drugs (NSAIDs) only made the attacks more frequent. His pulse was choppy and wiry, and his tongue scarlet-red with bulging pin-head veins on its lower surface. The left big toe was substantially swollen, had a purple-black-crimson-red colour, bright as if polished, and was untouchable.

As understood by Western medicine, gout is the result of too much uric-acid in the blood, due to a metabolic disorder in the break-down of purines. Purines are prevalent in red wine, anchovies, organ meats and other foods. The uric-acid crystals sink to the lower parts of the body and create a sediment in the small joints of the toes and metacarpal bones. These microscopic nail-shaped particles cause the inflammation and the severe pain typical of gout. The incidence of renal and urinary calculi is very high in people suffering from gout, mainly due to the sedimentation and coagulation of these uric-acid crystals in the kidney tissue.¹

In traditional Chinese medical theory, the phenomenon of gout is often ascribed to damp-heat affecting the joints, at least it is often presented as such in Chinese medical schools. The logic behind this is the appearance of the gout mostly

in the lower parts of the body (a typical sign of pathogenic dampness), the swelling of the affected joint, and the red and hot manifestation. I disagree with this categorisation. In my opinion, the disorder must be viewed in two phases. The first one, the 'ben' or the cause of the disease, may well be attributed to a damp-heat pathogen flowing downwards due to kidney-liver imbalance. Kidney qi, or yin, deficiency, is the basic pattern in the genesis of gout. The kidneys are too weak to eliminate the excessive heat by their separation process, thereby transmitting the pathogen down and into the liver. The liver further develops a damp-heat condition of its own, further transmitting the pathogen into the blood that it stores. When this heavy pathogen reaches the lower parts of the body, it naturally sinks into the feet articulations and creates the 'biao' – the manifestation of the disorder – the acute second phase. Being so closely affiliated with the blood, and having such a toxic heat quality, the pattern turns into a blood stasis disorder. Its manifestations are:

- a sharp, localised, pricking pain
- a marked swelling of the affected joint
- a dark red-crimson colour
- a taut shiny skin
- sharp pain is usually relieved to some extent by a hot shower
- a wiry and choppy pulse and blood stasis signs on the tongue

According to this analysis of the pathogenesis and nature of the gout disorder², I commenced the treatment by performing a strong blood dispersion acupuncture. I bled the points Yinbai SP-1 and Dadun LIV-1 of the affected toe with the pyramid (bleeding) needle, and squeezed out a few drops of black blood. I then punctured Hegu L.I.-4 and Sanyinjiao SP-6 using reducing manipulation by quick lifting and anti-clock-wise rotation movements, until the patient could not tolerate the manipulations further. The needles were left in-situ for 30 minutes. When Joseph left for home after this session, his pain had already diminished considerably. The following day, despite the fact that he had much less pain and swelling, I repeated the same procedure, adding Quchi L.I.-11 to the prescription, along with Taichong LIV-3, Xingjian LIV-2 and Taibai SP-3 on the left foot only. Quchi L.I.-11 strongly cools the blood and, matched with Hegu L.I.-4, invigorates the blood flow and disperses blood stasis. When these two points are combined with Taichong LIV-3 and Sanyinjiao SP-6, the effect is amplified, and especially so if the needling is unilateral and restricted to the affected limb. It took three more consecutive sessions to eliminate the current attack completely, a fact which gained Joseph's gratitude and trust for our future encounters.

Being worried about the clear pulse and tongue signs of a pronounced blood stasis condition in my patient, I strongly recommended to him to pursue periodical treatments, in order to eliminate future complications. To be frank, what I had in mind was possible recurrences of gout rather than toxic abscesses that might endanger his whole foot. He promised to follow my specific dietary and behavioral

instructions, but could not commit himself to subsequent treatments.

The abscess

About two years following the gout treatment, Joseph called me again with a desperate and urgent tone in his voice. Three weeks ago, an abscess started to develop on his left dorsal surface. The abscess developed very rapidly, becoming deeper and wider all the time, exuding pus and inflaming the whole foot. It did not respond to any of the treatments offered by conventional medicine and eventually, gangrene bacteria were detected in histological tests. Joseph said that the doctors were determined to amputate his left foot above the malleolus.

Relying on my past experience with this disorder, I told Joseph that he must come for daily treatments, and that he should make up his mind urgently. In fast developing gangrene, time is of the utmost importance. Thus, Joseph came to me for a second round of emergency treatment.

He presented with a large and developed ulceration on his left dorsal skin. The ulceration exuded pus and was bandaged tightly. The smell was awful and the whole foot and shin was considerably oedematous and puffy. The skin around the ulceration was remarkably dark, almost black, and the rims of the wound had a rotten appearance. Joseph looked very emaciated, depressed and suffering. His pulse was very weak and thin, with the chi (root) position very empty, but the left cun (heart) position was wiry and deficient. The tongue was much paler than I remembered from his previous visit, yet the bulging pin-head veins underneath were still present. In overall appearance, the tongue seemed swollen and dull, coated by an excessive thick and greasy grey coating. Joseph also had a low fever.

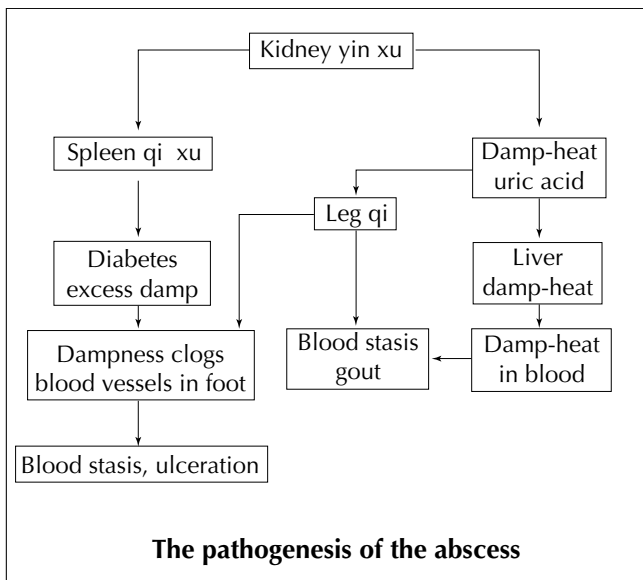
Summary of symptoms and signs

- ulcerative abscess on the left dorsal surface
- an excessively oedematous foot and shin
- black skin colour around the abscess
- an offensive putrid smell and exudation of pus
- a thin and deficient pulse with the Heart position also wiry
- a swollen tongue, with greasy grey coating and bulging pin-head veins underneath
- emaciation, weakness and low grade fever

Analysis and diagnosis

Recalling Joseph's medical history, we know that Joseph had had diabetes for several years, and that he was insulin dependent. We also know that he used to have recurrent attacks of gout, based on a kidney deficiency and a subsequent damp-heat condition. Diabetes mellitus, termed in Chinese xiao-ke (wasting and thirsting), is characterised mainly as a yin deficiency pattern³. Kidney yin deficiency may lead to stomach and/or lung yin deficiencies, giving rise to the typical symptoms of excessive hunger or thirst, excessive urination and thinning of the flesh.

In Joseph's case, the kidney yin and qi deficiency led also to the accumulation of damp-heat pouring down and the appearance of gout. As explained above Joseph had developed a pronounced blood stasis condition. In the acute stage, it caused the extremely painful gout attacks and in the later, chronic stage, it caused the ulceration of the skin and the formation of the abscess. Thus, the puffy and oedematous foot and shin reflected 'leg-qi' disorder with accumulation of dampness, while the black colour of the surrounding skin and the abscess itself, pointed to advanced blood stasis, to the point of decaying flesh. Hence, we can see a yang condition on the verge of turning over to a yin condition. The thin and deficient pulse qualities, the dull and lifeless tongue, the emaciation, all point to a developing deficiency condition. Yet, the bulging tongue veins, low grade fever and the inflamed abscess, mark the transition from yang to yin.



The treatment guidelines

In acute or life threatening diseases, the treatment principle is always to eliminate, as fast as possible, the acute manifestations. There is always time to deal with the underlying cause after the acute symptoms have disappeared. In view of this principle, I realised that two major efforts had to be undertaken simultaneously:

- i. Eliminate the acute spread of the toxic inflammation of the abscess and the blood.
- ii. Heal the abscess itself.

In terms of Chinese medicine, I had to invigorate the blood, eliminate fire-toxin and drain excessive dampness. Being aware that this fire-toxin was extremely fast spreading and represented a real life threatening factor, I insisted that Joseph have an X-ray of his foot every three days. This precaution was needed in order to make sure that the gangrene had not penetrated the bone.

In order to achieve the treatment goals set out above, I chose the following points as my opening point prescription:

- Hegu L.I.-4 bilateral, Sanyinjiao SP-6 and Yinlingquan SP-9 left side only.
- Bleeding of all the jing-well points of the left foot.
- Taichong LIV-3, Neiting ST-44, Xiashi GB-43 on the left side only.

Explanation

Hegu L.I.-4, Sanyinjiao SP-6 and Yinlingquan SP-9 served as a combination to invigorate the blood in the affected limb and eliminate dampness. L.I.-4 is a major point for qi and blood invigoration throughout the whole body. This is mainly due to its role as a yuan-source point of the yangming channel, the richest of the six channels in qi and blood. Sanyinjiao SP-6 and Yinlingquan SP-9 are a well-established point combination for the purpose of eliminating excessive dampness, both systemically and locally.

Thus, the three points together, especially when confined to only one leg, wield a strong invigorating influence over the qi and blood of the affected limb. Sanyinjiao SP-6 and Yinlingquan SP-9 are both situated on the Spleen channel which is deeply involved in the creation and spread of internal dampness pathogen. Using these points enhances the activity of the Spleen, tonifies its yang qi and eliminates dampness from the very source. Sanyinjiao SP-6 is also very much involved in blood pathologies. It is the meeting point of the liver, spleen and kidney channels, belonging to the three major zang involved in blood creation, storage and maintenance in the body. Sanyinjiao SP-6 is therefore always utilised in blood disorders, especially those of the lower part of the body.

The bleeding of the jing-well points of the foot has strong blood moving and toxin eliminating properties. The jing-well points are almost always used in acute disorders, usually involving heat or fire pathogens. A very common use of this principle for example, is the bleeding of Shaoshang LU-11 in acute tonsillitis. The jing-well points, being so anatomically close to the focus of the disease in this case, enhanced their efficacy.

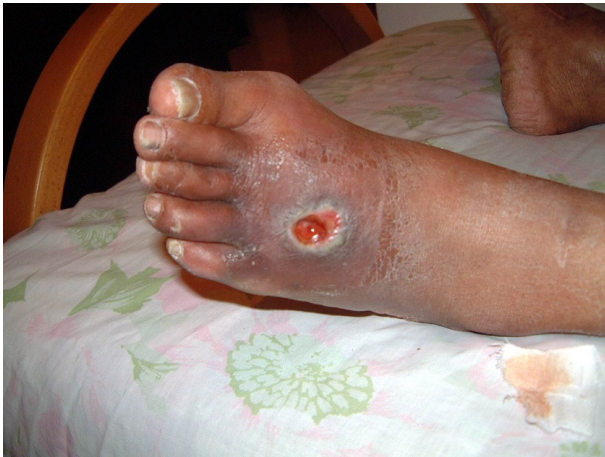Taichong LIV-3, Neiting ST-44 and Xiashi GB-43 were chosen primarily because of their anatomical location near the site of the abscess. They are strong and effective points, situated on three different channels, all of which traverse the dorsal region. Their use was, therefore, intended to affect qi and blood circulation in the dorsal region and, for that reason, they served as a local point-cluster.

The treatment process

These point combinations were utilised for 10 consecutive sessions over 10 days without a break. Each session lasted 30 minutes and the needles were manipulated with reducing technique every 10 minutes. Joseph was instructed to remove the bandages he had been given by the hospital, and stop applying their ointments. I forbade him from taking any further treatments suggested to him by the hospital staff, excluding the X-ray which I insisted he continue. He was told to expose the wound to the air as much as possible, except when he was traveling to see me. At home, he needed

to apply a strong green tea dressing on the wound, three times a day. In addition, Joseph was requested to avoid coffee, alcohol, spicy and fried food, red meat and dairy products in addition to following his regular diabetic regime.

After five sessions the fever subsided completely and the foul smell of the abscess began to diminish. After the 10th session the swelling of the dorsal region decreased, but not that of the entire ankle or the shin. The abscess started to close in, and new pink flesh started to regenerate at the proximal corner, as evidenced in the photograph below.



At this stage also, the black skin colour started to lighten at the far margins of the inflamed mound and the pulse acquired more strength and was less thin and deficient.

Now Joseph started to regain hope and optimism. So did his relatives, who had accompanied him to the treatments, a fact that relieved the tense and apprehensive atmosphere which characterised the first sessions.

At this point, I decided to change the treatment prescription and shift the main effort from clearing the fire-toxin to directly healing the wound. The points prescribed for this new purpose, were as follows:

- Hegu L.I.-4 bilateral, Sanyinjiao SP-6 and Yinlingquan SP-9 left side only (i.e. unchanged).
- “Ring the Dragon” technique.⁴
- Shangqiu SP-5, Zhaohai KID-6, Jiexi ST-41, Qiuxu GB-40

The first three points were left in the prescription without any change. I considered this trio as the main “engine” for the purpose of mobilising and invigorating qi, blood and lymph circulation throughout the left leg and foot. I have had years of experience applying this specific combination for similar disorders with undoubted efficiency. For me, it was indispensable.

Explanation

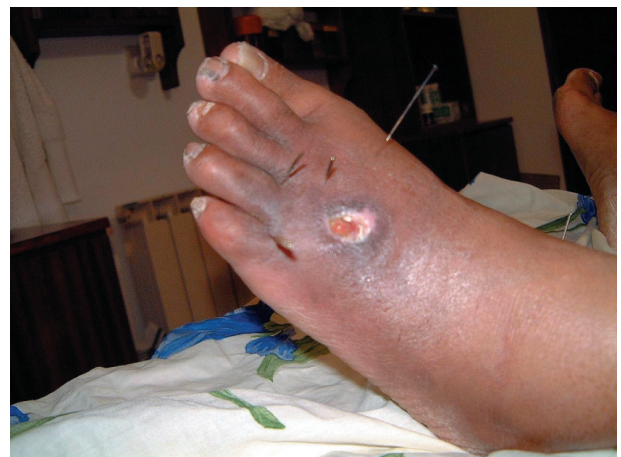Shangqiu SP-5, Zhaohai KID-6, Jiexi ST-41 and Qiuxu GB-40 were chosen as a different point-cluster, for the purpose of dispersing the pronounced oedema around the ankle joint. The points were chosen particularly due to their location at the obvious spots of the oedematous mounds. They were manipulated vigorously by the ‘huici’ needle technique, in order to disperse and dissolve the accumulation of dampness around the ankle. The huici technique uses dispersion

manipulations in three different angles. The needle is inserted swiftly to the deep level and twirled in a wide amplitude, and by quick withdrawals to the surface, as if pulling the qi outward. It is then lifted to the surface and redirected, diagonally, at another angle and manipulated again in the same fashion, then redirected at another, third, angle. The needle is then left in-situ.

However, the main acupuncture technique at this stage of the treatment, was the “Ring the Dragon” technique. With this method, the wound is surrounded by several needles, usually between 3-6 one inch needles. The needles are placed on the healthy margins of the wound, a few millimeters away, at a slanted angle with the needle tip directed underneath the margin of the wound, some 1-2 cm in the direction of the centre of the ulceration. It is then left in-situ without further manipulation. At the end of the session, some 30 minutes later, the “Ring the Dragon” needles are pulled out. In many instances, there are a few drops of blood exuding from the points. This slight bleeding must be encouraged by lightly pressing around the point (and not pressed to discourage bleeding). The tiny bleeding enhances micro-circulation at the rims of the abscess.

The “Ring the Dragon” method is vital in the treatment of ulcerations, boils, abscesses, scars and practically all kinds of localised skin disorders. The technique stimulates the margins of the disorder and enhances blood circulation there, thereby accelerating the recovery of infected skin tissue. I have found this technique tremendously helpful in a wide variety of skin disorders, and in fact, it should not be overlooked in the treatment of a localised skin disease of any kind.

The above delineated needling procedure was carried out for 12 more sessions. At the 16th session, I took another photograph of Joseph’s left foot, shown below. The abscess seemed much shallower, the new pink flesh that started to form on the proximal edge had increased its dimensions, the putrid smell had almost completely disappeared and the black skin around the wound had taken a lighter shade.



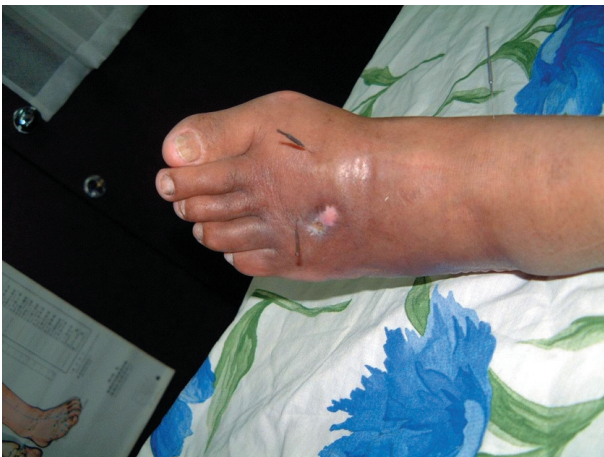Throughout the last 12 sessions I occasionally introduced other points to the prescription. These were:

- Quchi L.I.-11 – a point known for its ability to clear heat

- from the blood and help regenerate new skin.
- Weizhong BL-40 – for the same reason, only anatomically closer to the disease focus.
 - Occasionally, points from the first prescription, such as Neiting ST-44 and Taichong LIV-3 were used for their local as well as systemic effect.

At home, Joseph was instructed to apply self treatment, aided by his wife, utilising the “Chopsticks Acupuncture technique”⁵, on points Shenshu BL-23 and Sanjiaoshu BL-22. These points were chosen in order to mildly stimulate the kidneys and sanjiao, in order to enhance the absorption of excess fluids and resolve the oedema. These points were stimulated twice a day by the couple, for two more weeks.

On the 22nd session I considered the treatment for the abscess to be completed, as the wound had healed completely (see photograph below). Joseph received four more treatments in the course of the next 12 days, whose aim was to resolve the remnants of the oedema. This objective was completed successfully, as the ulceration, the cause for the local inflammation and congestion, had now ceased to exist.



This time, I succeeded in persuading Joseph to continue with therapy once a month, in order to keep a check on his basic condition which had permitted the development of the ulceration. On these regular visits, he receives acupuncture treatments aimed at strengthening his kidney yin and qi and eliminating the damp-heat and heat pathogens from the blood. He also self-applies regular treatments utilising the Chopsticks Acupuncture⁵ technique, on points that I have marked out on his body, and keeps to a strict diet.

All in all, his condition remains stable, and in the year following treatment of the ulceration, no other incidents of either gout or other ulcerations have occurred.

Notes

- 1 The Merck Manual on the web: http://www.merck.com/merckshare/mmanual_home2/sec05/ch070/ch070b.jsp
- 2 A discussion on this topic may be found on the internet discussion forum, at: <http://www.acumedico.com/discus/messages/25/129.html?1073471274> (Readers are most welcome to post their opinions and insights concerning the pathology involved in gout).

- 3 Diabetes Mellitus by Clinton J. Choate, *Journal of Chinese Medicine*, Issue 59, January 1999.
- 4 *Journal of Chinese Medicine*, Issue 46, September 1994, p.7.
- 5 *Chopsticks Acupuncture* by Shmuel Halevi, Trafford publishing, B.C. Canada, Feb. 2003 (<http://www.trafford.com/robots/02-1326.html>).

Shmuel Halevi Ph.D. practices Chinese medicine in northern Israel, in Upper Galilee. Contact:
 email: HaleviS@AcuMedico.com
 Website: <http://www.acumedico.com>